

4.6.3 Posterior lens luxation

is not considered an emergency. The lens usually luxates into the posterior segment as a result of vitreal syneresis, or liquefaction.

Clinical signs

- increased anterior chamber depth
- vitreal herniation
- usually fixed mydriasis

Therapy

- ✓ surgical removal of a posteriorly luxated lens is not recommended.
- ✓ Since the lens may often move freely from an anterior to a posterior position, the use of a topical pupil constrictor is suggested, provided that the lens is in the posterior segment.
- ✓ Glaucoma and retinal degeneration are frequent associated conditions

4.7 Glaucoma

Glaucoma can be defined as a progressive optic neuropathy, associated with a level of IOP (intraocular pressure) non-compatible with the normal function of retinal ganglion cells and optic nerve head, thus leading to blindness.

Glaucoma can be:

- primary
- secondary to
 - ✓ uveitis
 - ✓ lens luxation
 - ✓ neoplasia
 - ✓ cataracts
 - ✓ trauma
 - primary
 - iatrogenic
- ✓ Several canine breeds are predisposed to primary glaucoma. Cocker Spaniels, Bassett Hounds, Siberian Huskies, Boston Terriers, Chow Chows, Norwegian Elkhounds and Wire Fox Terriers are among the most commonly involved breeds.
- ✓ In cats primary glaucoma is a rare condition and Siamese and Burmese breeds seem over-represented.
- ✓ Secondary glaucoma develops as a result of previous intraocular problems, with neoplastic and uveitic diseases being the most common causes. In cats, the presence of glaucoma is almost always secondary to uveitis or neoplasia: any case of feline glaucoma should always prompt investigation of the primary underlying cause.

A more practical clinical classification of glaucoma include acute and chronic.

👁 *Obviously acute glaucoma represent an emergency and since optic nerve degeneration may occur within a few hours of the pressure spike, acute glaucoma is one of the few real ocular emergencies*

Primary narrow or closed angle glaucoma is the most common cause for glaucoma emergency cases. In acute congestive cases, the onset is usually sudden.

The owner notices:

- ocular pain with squinting
- third eyelid protrusion
- ocular redness
- corneal cloudiness
- discharge
- Vision loss is often present, but is rarely noted by owners, who cannot usually detect unilateral vision impairment.

- Often, the problem will develop at night (pupil dilation)
- Signs are usually unilateral, but the disease will eventually become bilateral
- Patients are commonly depressed and non-responsive.

Vision evaluation is often difficult, due to the patient's discomfort and altered status. In these cases, testing of indirect PLR in the contralateral non-affected eye is very helpful, and critical for further therapeutic decisions.

The veterinarian notices:

- blepharospasm
- third eyelid protrusion
- corneal edema
- conjunctival hyperemia and episcleral congestion
- fixed mid-range to dilated pupil
- vision loss

Definitive diagnosis is reached through assessment of IOP by applanation tonometers, indentation tonometers or, recently, rebound tonometers.

Normal IOPs range in dogs is roughly 8 - 22 mm Hg,

In acute congestive glaucoma, IOP is extremely elevated, usually greater than 40 mmHg, and can reach values as high as 60-70 mmHg.

Answering certain key questions is vital as soon as glaucoma is diagnosed. The answers will help guide which therapeutic options are most appropriate.

- acute vs. chronic glaucoma
- presence or absence of vision
- primary vs. secondary glaucoma
- presence or absence of intraocular neoplasia

Table 2 lists the most common ocular signs that help distinguish between acute or chronic disease.

👁️ *Buphthalmos is NOT a sign of acute glaucoma!*

Table 2

Sign	Acute	Chronic
Pain	+++	-/+
IOP	60ish	40ish
Vision	+/-	-
Pupil	midrange	Dilated
Corneal edema	+ /++ /+++	-/+
Haab's striae	-	+
Buphthalmos	-	+

In case of acute glaucoma (few hours-24 hours), with positive dazzle reflex and/or a consensual PLR in the contralateral eye, or even when vision has just been recently lost, aggressive medical protocols need to be started as soon as possible.

- ✓ The first goal is to recover vision, or to preserve it for as long as possible. This for all intents and purposes translates into decreasing intraocular pressure to normal values. However, at the time of diagnosis, the neuroretinal damage may be severe enough to have already irreversibly compromised vision.
- ✓ The second goal is aimed at decreasing the patient's discomfort.

Commonly used topical medications:

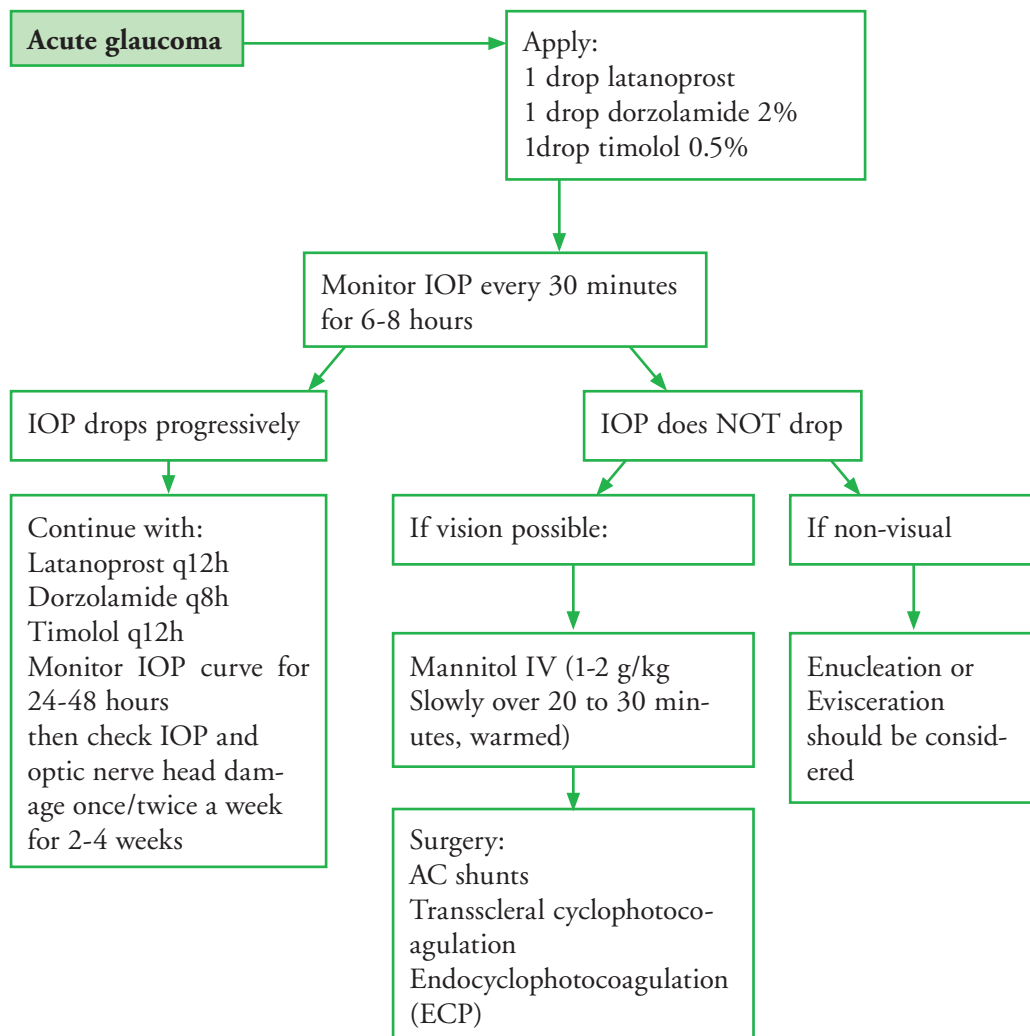
- Prostanoids (not effective in cats)
 - latanoprost 0.005% SID-BID
 - travoprost 0.004%
 - bimatoprost 0.03%
 - unoprostone 0.15%
- Carbonic Anhydrase Inhibitors (CAI)
 - dorzolamide 2% BID-TID
 - brinzolamide 1% SID-BID
- β -blockers
 - timolol 0.5% BID

(Timolol should be administered cautiously in dogs with heart disease and especially in small dogs with bradycardia cardiac arrest can develop, (Sick Sinus Syndrom))

There is no additional benefit from oral CAI when topical ones are used. There is a potential for systemic side effects with oral CAI (potassium depletion and weakness, acidosis, vomiting).

Mannitol is no longer a primary medication for acute glaucoma management, it is reserved for the few cases that do not respond to topical therapy.

Table 3 Protocol for cases of acute congestive glaucoma



- ✓ Chronic cases do not need emergency treatment since the eye is usually already buphthalmic and blind. Enucleation or evisceration should be considered.
- ✓ However, in case of primary glaucoma, the contralateral eye should promptly be started on anti-glaucoma medications. Prophylactic treatment may delay the onset of glaucoma in the second eye. A topical combination of dorzolamide 2% and timolol 0.50% twice daily is usually used.

- ✓ The presence of intraocular neoplasia is not an uncommon cause for secondary glaucoma in cats and dogs.
 - ocular ultrasound should always be performed,

After management of the acute episode, patients should be routinely rechecked. Owners have to be aware that pressure spikes may occur unexpectedly.

- 👁️ *Owners should therefore be advised to bring the patient in on an emergency basis every time squinting and redness is noticed.*

The owner should always be educated about the fact that glaucoma is a frustrating and poorly controlled disease, and enucleation or evisceration is often the ultimate outcome.

4.8 Ocular Media Opacity

A list of the most common causes of ocular opacities is listed in Table 1.

4.8.1 Protrusion of the third eyelid

Most owners are not even aware of the existence of the nictitans in their pet, and its unusual protrusion is often mistaken for a “film over the eye”.

The most common causes for third eyelid protrusion are:

- ocular pain (see previous chapter)
- orbital space-occupying diseases
 - cellulitis/orbital abscesses
 - myositis of the masticatory muscles
 - neoplasia
 - infectious granulomas
- Horner’s syndrome
- dysautonomia
- Haw’s syndrome in cats (bilateral protrusion of the third eyelid)
- enophthalmos due to dehydration/weight loss
- tetanus
- cannabis and strychnine poisoning
- rabies

The patient’s history and signalment, together with a complete physical and ocular examination, will help to identify the primary cause. Often, additional diagnostic imaging is required (ocular ultrasound, CT scan, MRI). Of all the above listed causes of ocular pain, cellulitis, myositis, toxicities, tetanus and rabies may be quite sudden in onset: they are considered true emergencies and should be addressed as soon as possible.