

# LAMINITIS

Laminitis is a common but still incompletely understood condition which causes varying degrees of foot pain, from the slightly potterly pony to severe life-threatening lameness. Owners often underestimate its potential to cause long term unsoundness. It is not uncommon for severe and uncontrolled cases to require euthanasia on the humane grounds of incurable suffering.

## ***What is laminitis?***

Laminitis, in its simplest form, is inflammation of the sensitive layers (laminae) of the hoof. The coffin bone is suspended within the hoof by many interdigitating specialised 'leaves' (laminae) composed of sensitive tissue. In laminitis these soft tissues become damaged resulting in pain, inflammation and, in some cases, the formation of gaps between the laminae. In very mild cases, appropriate treatment will resolve the problem quite quickly with no lasting effect. If the inflammation is more severe and progressive, the sensitive laminae may lose their blood supply and die with consequent loss of support between the pedal bone and horny hoof wall. This can result in separation of the pedal bone from the hoof with rotation and/or sinking of the bone within the hoof. As the horse stands and moves on its feet, penetration of the sole by the tip of the pedal bone can follow, with fatal consequences.

## ***What causes laminitis?***

The underlying problem is interference with the blood supply to the sensitive layers of the foot. Conditions which cause this either directly or indirectly include:

- overfeeding
- excessive eating of carbohydrate, e.g. cereals
- toxemia associated with infections, especially bowel infections
- adverse reactions to certain drugs including corticosteroids and some antibiotics
- severe injury e.g. fracture or joint infection resulting in increased weight-bearing on the opposite limb
- neglected feet or poor trimming and shoeing resulting in long toe/low heel conformation
- excessive concussion due to fast exercise on hard ground
- drinking a large quantity of cold water when overheated
- Horses or ponies with a history of laminitis are susceptible to recurrence. Some old horses which have chronic or recurrent laminitis have tumours of their pituitary glands (pituitary adenoma, causing Cushing's syndrome) or 'metabolic syndrome' as a contributing factor.

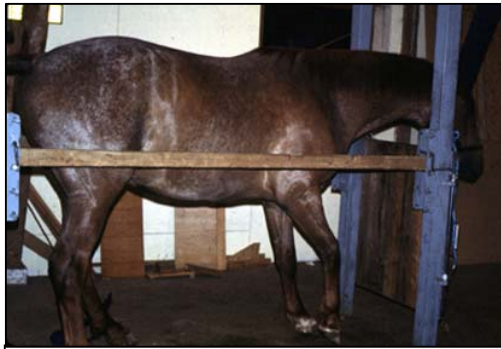

Soaked feed in manger

## ***How can I recognise the early signs?***

In mild cases of laminitis, the horse or pony may appear slightly 'pottery'. The forelimbs are most commonly affected although it is possible for the hind limbs only or all four feet to be affected. Often one foot is worse than the others. The affected foot or feet may appear abnormally warm to the touch and the pulse taken at the heel's arteries may appear particularly strong. Laminitic horses will often stand with hind limbs well under the body and forelimbs stretched out in front, in an effort to keep weight off the painful front feet. This characteristic stance is almost diagnostic of laminitis. Affected horses will move with their

heels landing first to try to avoid concussion to the painful toe region. If all four feet are affected, they may lie down for long periods or may constantly lift their feet alternately from



Horse with laminitis shifting its weight off its front feet

the ground. More severe cases result in sudden inability or reluctance to move at all and horses with severe rotation and sinking will often be unable to bear any weight on the affected limb or limbs.

Horses which have recovered from laminitis, or chronic (long-standing) cases often have an altered hoof shape with long heels and a convex rather than concave sole. These horses must be monitored very closely for signs of foot pain and require regular remedial farriery and monitoring x-rays.

It is important to realise that laminitis can progress from mild to severe even if early treatment is instigated. Early warning signs must be heeded and action take immediately.

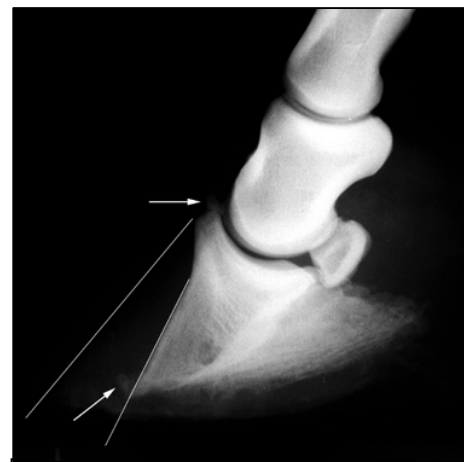
### ***What can be done?***

It is essential to call your veterinarian early and let him/her monitor your horse with x-rays. Many mild cases respond to stable rest, a restricted diet, anti-inflammatory medication e.g. phenylbutazone, and removal of the cause of the laminitis, where this is known. More severe cases may also need medication to reduce blood pressure (acetylpromazine), remedial hoof trimming and shoeing and anti-inflammatory medication for a prolonged period (often many months). In cases of chronic pedal bone rotation, progressive remedial trimming monitored by x-ray examination to shorten the toe and lower the heel will gradually return the hoof to a more comfortable conformation in relation to the pedal bone. In horses where there is rotation or sinking of the pedal bone, radical trimming and shoeing with a wedge may be combined with surgery to cut the deep flexor tendon in an attempt to prevent further rotation. In cases where the pedal bone has penetrated the sole, the prognosis is hopeless and euthanasia should be performed on humane grounds.

Many other treatments have been suggested for laminitis in horses, with opinions on their suitability and efficacy varying, even amongst experts.

### ***How can it be prevented?***

Ponies have evolved in the wild to walk long distances to find sparse poor quality food and any pony with access to good grazing should be watched carefully for signs of becoming overweight or pottery. When grass growth is lush, grazing should be restricted by either stabling on shavings, peat moss or shredded paper for part of the day and exercise should be increased to regulate body weight. Sudden increases in concentrate food intake should be avoided and fast work on hard surfaces should be avoided. Do not ignore illnesses associated with infections, especially colic and diarrhea (colitis) or uterine infections (metritis) following retained placenta. Both of these conditions present a high risk for producing laminitis. In such cases, veterinary help should be sought without delay.



X-ray (radiograph of horse's foot with chronic laminitis showing rotation of pedal bone

Conclusion

Laminitis can present with signs varying from a minor 'unlevelness' to a life threatening condition and should never be treated lightly. Even mild cases can take many months to improve and some horses never regain full soundness. Significant numbers of cases of acute laminitis, associated with toxemia are unsaveable, even with high quality intensive care. Prevention is much better than cure and many, although not all, cases can be prevented by good management.

---

*This client information sheet is based on material written by Deidre M. Carson, BVSc, MRCVS & Sidney W. Ricketts, LVO, BSc, BVSc, DESM, DipECEIM, FRCPath, FRCVS.  
© Copyright 2005 Lifelearn Inc. Used with permission under license. November 17, 2006*