

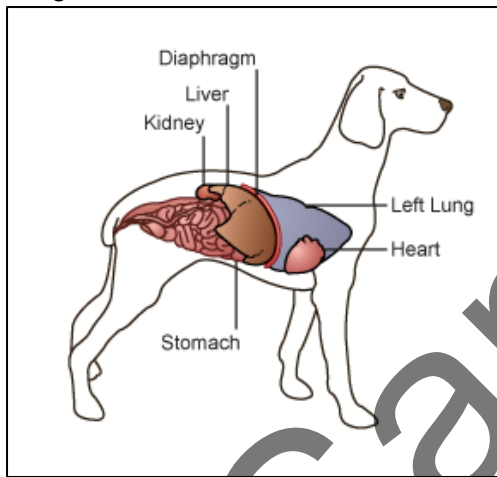
ABC Animal Hospital  
123 Main Street  
Anytown, Anyplace, AnyCountry  
Zip/Postal Code

Phone: (999) 123-4567 Fax: (999) 234-5678 info@abcanimalhospital.com

## DIAPHRAGMATIC HERNIA IN DOGS

### ***What is a diaphragmatic hernia?***

The diaphragm is the muscular partition that separates the abdomen and the chest. Tearing or disruption of this thin muscle is called a diaphragmatic hernia or diaphragmatic rupture. The terms are often used synonymously. One form of diaphragmatic hernia, a peritoneal-pericardial diaphragmatic hernia (PPDH) is congenital, and is due to defective development of the fetus. This condition is most



often found in puppies or kittens and should be considered separately from the traumatic type of diaphragmatic herniation or rupture. Congenital diaphragmatic hernias are a recognized problem in Weimeraners and cocker spaniels.

Once a tear in the diaphragm is present, abdominal contents such as the stomach, liver, and intestines are able to enter the chest cavity.. This compresses the lungs and prevents them from fully inflating, causing respiratory distress. The abdominal tissues may irritate the heart muscle, which may cause abnormal heart rhythms. Fluid may leak into the chest cavity from the abdomen, further complicating and

worsening cardiopulmonary function.

### ***What causes a diaphragmatic hernia or rupture?***

The most common cause of diaphragmatic hernia is blunt trauma. This type of trauma can occur after a fall from a high place (such as out of a window), an automobile accident or a blow to the abdomen. Congenital diaphragmatic hernias are less commonly seen in veterinary hospitals.

### ***What are the clinical signs of diaphragmatic hernia?***

Clinical signs are dependent on the severity of herniation. With small tears or in dogs born with a diaphragmatic hernia, there may be no discernable clinical signs. The pet owner may report mild breathing difficulties, especially when stressed or exercising, and periods of mild gastrointestinal upset. In severe or acute cases, there is often respiratory distress, an abnormal heart rhythm, muffled heart and lung sounds and other signs of



systemic shock. The abdomen may feel empty when palpated.

### ***How is a diaphragmatic hernia diagnosed?***

Diagnosis is based on medical history, physical examination and radiographs. Blood and urine tests may be performed if the patient is showing signs of shock. In certain cases, ultrasound or special radiographic dye studies will be required for definitive diagnosis.

### ***What is the treatment for diaphragmatic hernia?***

If there is a history of recent trauma, the dog must be stabilized before the hernia can be corrected. Some patients will require emergency thoracocentesis (a chest 'tap') to remove any fluid that is accumulating in the chest cavity. Once the patient is stabilized and a diagnosis is made, the hernia must be corrected surgically. In congenital forms, surgical intervention as early as possible is important to prevent organ entrapment or scarring between the intestines and the chest cavity. Many congenital diaphragmatic hernias are discovered during ovariohysterectomy surgery, and are corrected at that time.



### ***What is the prognosis?***

The prognosis for any patient with diaphragmatic hernia is always initially guarded. It improves once the patient has been stabilized and the heart rhythm is normal. After surgery, the risk of a condition called re-expansion pulmonary edema requires that a guarded prognosis be given for at least twenty-four hours after successful surgery. The prognosis for young pets with congenital diaphragmatic hernia is guarded to good, and is based on the specific findings during surgical correction.

### ***If the patient stabilizes with medical treatment, is it possible to avoid surgery?***

In trauma cases, adhesions may form between the lungs and any herniated abdominal contents after approximately seven days. These adhesions will affect the ability of the lungs to inflate properly, and will cause the surgery to become more complicated and dangerous. However, each case needs to be assessed individually.